In-Vivo Histopathologic Assessment of High Average Power Diode Laser for Permanent Hair Reduction Using SHR™ Volumetric Heating Technique

Tania Ap. Meneghel, MD and Maria Leticia Cintra, MD
Renaissance , Medical Center for Prevention and Rejuvenation
Jardim Girassol Americana, São Paulo, Brazil

INTRODUCTION

Laser hair reduction has been used for both aesthetic and therapeutic purposes (e.g., folliculitis). However, hair reduction by means of lasers and light sources such as IPL, using the traditional method, has some disadvantages: pain, formation of erythema, crusting, pigmentary changes, as well as the use restriction in phototypes V and VI. Another obstacle is tanned skin, much appreciated in tropical countries. Thus, there is a widely recognized need for an improved method for laser hair removal that heats hair follicles to a sufficient temperature while delivering an optimal amount of optical energy to thermally alter hair follicle function.

We treated six female patients, age 24 - 45 and Fitzpatrick phototype II to V, for the purpose of permanent hair reduction of bikini line with the Soprano^{XL} laser diode system (Alma Lasers, Caesarea, Israel). The system operates at a wavelength of 810nm, with maximal fluence 10J/cm at a repetition rate of 10Hz and a spot size of 1.2cm^2 (average power > 100watt). The handpiece consists of a sapphire with contact cooling. The technique employed was constantly moving the handpiece across a defined area. Volumetric heating is achieved by employing continuous laser exposure on the pre-marked area of 100cm^2 until reaching a recommended accumulated energy of 10kJ. There is no need for the use of anesthesia. A thin layer of ultrasound gel was applied on the skin to allow smoother sliding of the handpiece at a speed of ~ 5cm/sec. The expected sequealae are edema and perifolicular erythema. Immediately after the procedure, we performed a biopsy of 3.5cm x 1.5cm in the suprapubic region. Another biopsy was taken 7 days later. Skin sections were stained with hematoxylin & eosin (H&E).

Results

All treated areas of the participants demonstrated the expected clinical end points during and after treatment that are believed to be consistent with clinical efficacy with other devices tested in our clinic. The SHR diode laser therapy resulted in perifollicular edema and erythema, and singed hair was often seen at the skin surface immediately post-treatment. On histology, examining immediately after-treatment, epidermis presented normal configuration and the keratin layer showed no particular changes in all cases. Interestingly, in all the slides follicular hyaline necrosis was observed (Table & Figure 1). Hyaline membrane is a thin, clear basement membrane between the outer root sheath and inner fibrous layer of a hair follicle.

Table 1. Patients' quantitative histopathology assessment immediately and 7 days after treatment

Patient	Age	Skin type	Hyaline necrosis immediately after	Hyaline necrosis after 7 days
DS	35	V	90%	60%
MS	33	IV	90%	50%
RS	33	IV	60%	80%
MAS	45	II	80%	80%
AF	32	III	90%	90%
RP	24	V	80%	60%

Figure 1. Coagulative necrosis and shrinkage of the central components of the hair follicle (a), with epithelial thinning and dilation (b).

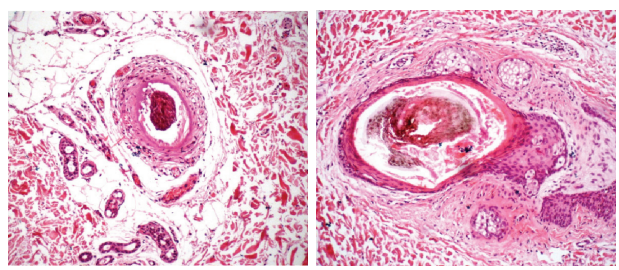

(a) (b)

Discussion

The biological control markers of hair following laser treatment may include hormones (androgens, 5-alpha-reducatase) non-steroidal (retinoic acid receptors, Vitamin D receptors, thyroid hormone receptors) growth factors (EGF, FGF), cytokines or stem cells. The role of stem cells in the formation of new anagen hair follicles makes these cells a logical target for destruction during light-based therapy to remove unwanted hair (1-3).

The SHR technique employs volumetric heating of the dermis, where the hair follicle is nourished and recycled. We speculate that since a certain temperature is required to eliminate hair follicles and their adjacent biological structures, it is apparent that temperature in the dermis, as a direct consequence of heat accumulation produced by the high average power of the SHR technique, can alter the hair structure and stem cell function. It is noted that although the fluence of each individual pulse delivered to the skin is relatively low (10J/cm^2), the rapidly-delivered pulses are, collectively, effective to heat the patient's dermis and to thermally injure the hair follicle.

Since the hair follicle is at least in thermal equilibrium with surrounding tissue, and the hair follicle is sensitive to heat, under the repetitive and prolonged laser exposure conditions, the hair follicle is thermally prone to heat insult/damage. Also, heat propagation from dermis to hair follicles may be the reason for cytoplasma changes and vacuola formation and hyaline necrosis as observed in practically all immediately-after samples. Due to the very high average power, the melanin in the hair follicle that is acting as chromophore conduct, experiences temperature rise above that of the dermis temperature. We postulate that because the dermis is a good heat conductor, the temperature of the hair follicle does not drop below the temperature of the heated dermis. In fact, the duration of each pulse in the SHR mode is less than the thermal relaxation time of most of the hair follicles, allowing a certain amount of delivered energy to be localized within the hair follicle. Thus, it is assumed that the temperature of the heated hair follicles exceeds the temperature of the heated dermis.

Thus, once the sub-dermal layer is sufficiently heated (45ºC -50ºC), individual pulses only need to provide enough energy to the hair follicle to raise the temperature of the hair follicle from a temperature at or above the heated-dermis temperature, to a temperature (50ºC - 55ºC) effective to impair the function of biological elements responsible for hair re-growth such as hormones, growth factors, or stem cells.

Conclusion

The use of the SHR volumetric technique in patients with dark skin types may substantially reduce pain or discomfort and minimize severity of blistering, scabbing, crusting and hyper/hypopigmentation. In addition, little to no prolonged epidermal effects, such as redness and inflammation of epidermis and no downtime before (no topical anesthesia) or after treatment makes the SHR treatment more comfortable and safer than traditional lasers systems.

Clinical Results

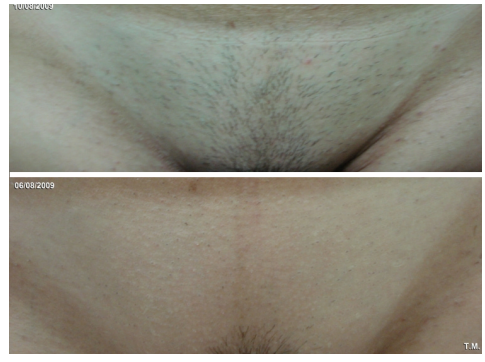

Before and 3 months after 4 treatments

Photographs courtesy of: Tania Meneghel, MD

References

1. *Orringer JS et al. The effects of laser-mediated hair removal on immunohistochemical staining properties of hair follicles. J Am Acad Dermatol 2006;55:402-7*
2. *Lepselter J, Elman M. Biological and clinical aspects in laser hair removal. J Dermatol Treat 2004;15:72-83.*
3. *Cotsarelis G. Gene expression profiling gets to the root of human hair follicle stem cells. J Clin Invest 2006; 116:1922.*

Alma Lasers
Wellbeing Through Technology

US Headquarters
485 Half Day Road
Suite 100
Buffalo Grove, IL 60089
Tel +1-224 377-2000
Fax +1-224 377-2050
contact@almalasers.com

International Headquarters
14 Halamish st. P.O.B 3021
Caesarea Industrial Park
Caesarea,38900, Israel
Tel +972-4-627-5357
Fax +972-4-627-5368
info@almalasers.com

PBSP10060901

© Alma Lasers, 2009. All rights reserved.